Iatrogenic Ostia between the Left Atrium and Esophagus: An Unusual complication of intracardiac manipulation

Arif Bin Saleh [1], *MD; Ndausung Udongwo* [1], *MD; Temidayo Abe* [2], *MD; Mihir Odak*[1], *MD; Nusha Fareen*[1], *MD , Laith Zamel*[1], *MD*

1. *Hackensack Meridian Health, Jersey Shore University Medical Center, NJ, United States.*
2. *Morehouse school of Medicine, Georgia, United States.*

Hackensack Meridian
Jersey Shore University
Medical Center

Introduction

- Radiofrequency catheter ablation (RFA) is an effective treatment for recurrent symptomatic atrial fibrillation despite medical therapy. Complications include cardiac tamponade , pulmonary vein stenosis, and rarely atrial-esophageal fistula (AEF). We present a case of infective endocarditis with septic embolic as a sequel of AEF from RFA.

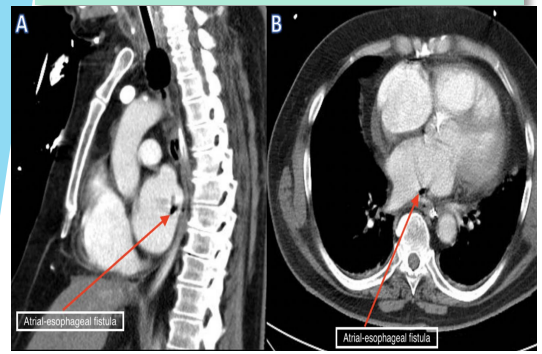

Figure 1. Chest computed tomography scan with contrast showing air contrast (red arrows) within the cavity of the left atrium in the sagittal (A) and axial (B) views.

Case Presentation

- A 77-year-old male with a history of persistent atrial fibrillation status post-posterior left atrial isolation 50 days prior presented to the emergency department with bilateral lower extremity weakness ongoing for an hour. In addition, he reported a non-productive cough, chest discomfort, and dysphagia. Vitals were BP 193/110, RR 28, HR 135, T 102.3 ℉, and 91% oxygen saturation on room air. Physical exam was significant for a decreased light touch sensation and 4/5 weakness in the bilateral lower extremity. Labs were significant for a white blood cell count of 17.9 10*3/uL (normal:: 4.5 - 11.0 10*3/uL), and troponin I of 1.76 ng/mL (normal:: <0.04 ng/ML). Electrocardiogram showed an irregularly irregular rhythm and no ST or T wave changes. Chest X-ray was unremarkable. Non-contrast computed tomography (CT) scan of the head showed areas of low attenuation in the left parietal, temporal, and occipital region, with no acute intracranial hemorrhage. Magnetic resonance imaging of the brain with/without contrast revealed hyperintensity in both cerebral and cerebellar hemispheres, consistent with subacute infarcts suggestive of embolic disease. Tissue plasminogen activator was contraindicated, as he was on apixaban. The patient was admitted for management of altered mental status and sepsis of an unknown origin.
- Due to associated chest discomfort and dysphagia, CT scan of the chest with contrast obtained revealed a small focus of air between the posterior wall of the left atrium and the esophagus. A few hours later, he deteriorated with worsened hypoxic respiratory failure, altered mental status, requiring intubation and mechanical ventilation. Cardiothoracic surgery was consulted, and he was taken to the operating room for open-heart surgery due to concern for AEF. Peri-operatively, a left atrial fistula measuring 0.5 cm was identified and closed. Also, a fibrinous material (3x4 cm) was identified and removed in the left inferior pulmonary vein. On post-op day 1, he underwent an upper endoscopy, and a 1 cm esophageal defect was closed. Biopsy from fibrinous material was positive for polymicrobial organisms (lactobacillus, candida, and prevotella), while blood cultures grew streptococcus anginosus. Despite treatment with aggressive intravenous antibiotics, the patient deteriorated with poor neurological function and ventilator dependency. A multidisciplinary team reached a consensus agreement for palliative measures. Unfortunately, he passed away shortly after.

Discussion

- To our knowledge, this case represents one of the few cases documenting life-threatening infective endocarditis with septic emboli as a complication of AEF from RFA. Therefore, clinicians should have a high index of suspicion due to associated grave prognosis.

References

1. Szegedi N, Suhai IF, Perge P, Salló Z, Hartyánszky I, Merkely B, Gellér L. Atrio-esophageal fistula clinically presented as pericardial-esophageal fistula. J Interv Card Electrophysiol. 2021 Sep;61(3):623-624.

2. Shim HB, Kim C, Kim HK, Sung K. Successful management of atrio-esophageal fistula after cardiac radiofrequency catheter ablation. Korean J Thorac Cardiovasc Surg. 2013 Apr;46(2):142-5.

The authors have no conflict of interest regarding this presentation to disclose.